



PRESENTING CLINICAL SIGNS

History: Grade IV/VI left-sided murmur with radiation to the right. Coughing after drinking the past few months.

DATE

12/2/22

ECHOCARDIOGRAPHIC FINDINGS

2D, M-mode, and Doppler study.

PERFORMED BY:

Tom McNeill

There is moderate left atrial dilation. The mitral valve leaflets are thickened and exhibit mild systolic prolapse. A moderate jet of eccentric mitral regurgitation is present. There is moderate left ventricular dilation. Left ventricular systolic function is hyperdynamic. The aorta and aortic valve are normal. Right atrial and right ventricular dimensions appear normal. The tricuspid valve is normal. The pulmonary artery and pulmonic valve are normal. No shunting lesions are visualized. No pericardial effusion or cardiac masses are seen.

INTERPRETED BY

Keith Blass, DVM,
MS, DACVIM
(Cardiology)

LA - 34.1 mm
LVIDd - 35.4 mm
LVIDs - 17.5 mm
FS - 50.6%
RA - 20.5 mm
LVOT - 1.52 m/s
RVOT - 0.87 m/s

PATIENT

Coco McKenna

ASSESSMENT/RECOMMENDATIONS

Degenerative mitral valve disease

SPECIES

Canine

This examination demonstrates moderate regurgitation of blood across Coco's mitral valve resulting from degenerative valve disease. Secondary to her regurgitation, Coco has moderate dilation of both her left atrium and left ventricle, though her left ventricular systolic function is well-preserved. Given the presence of moderate left atrial dilation, it's possible that mainstem bronchial compression could be contributing to Coco's cough. In addition to coughing, Coco is at risk for the development of exercise intolerance, syncope, and labored breathing, therefore, careful monitoring for these is recommended.

BREED

CKCS

SEX

FS

I recommend starting Coco on pimobendan (2.5 mg am, 1.25 mg pm), as this medication should help to slow the progression of her mitral valve disease. A cough suppressant, such as hydrocodone, may be given if Coco's cough becomes significant enough to warrant therapy.

AGE

8 y

A recheck echocardiogram is recommended in 6-9 month. Thoracic radiographs are recommended if Coco's cough worsens, or if she experiences labored breathing.

WEIGHT

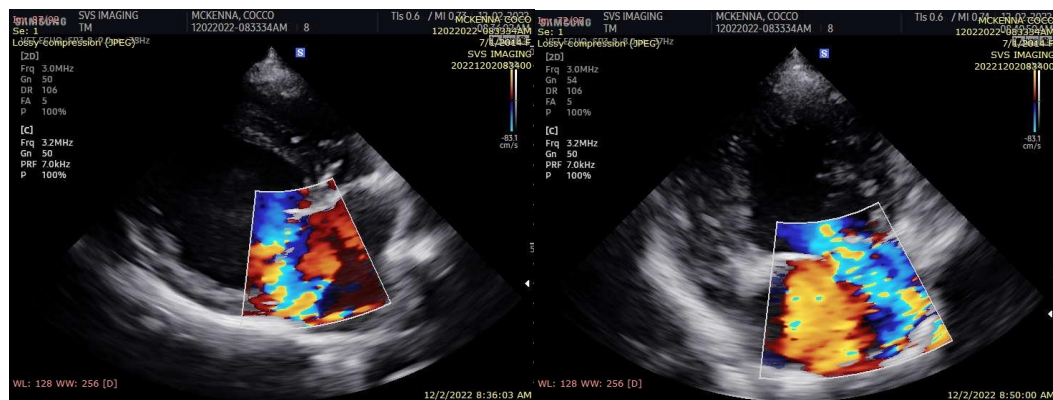
14 lb

HOSPITAL NAME

SVS Imaging CT

REFERRING VET

Dr. Ludwig





DATE 12/2/22 The information and recommendations provided are based on the images presented by the referring veterinarian. No evaluation can be communicated regarding pathology that was not visible in the image/video clips provided.

PERFORMED BY: Tom McNeill Thank you for this referral. If the clinical or image interpretation does not parallel your findings or if I can be of any further assistance please contact me.

INTERPRETED BY: Keith Blass, DVM, MS, DACVIM (Cardiology)
KeithBlass@gmail.com
631-804-5754

Keith Blass, DVM,
MS, DACVIM
(Cardiology)

PATIENT

Coco McKenna

SPECIES

Canine

BREED

CKCS

SEX

FS

AGE

8 y

WEIGHT

14 lb

HOSPITAL NAME

SVS Imaging CT

REFERRING VET

Dr. Ludwig